



Dr. Andrea Wernham

Veterinary Dental Practitioner

The Veterinary Dental Practitioner (VDP) program was established by Dr. Brett Beckman, a board-certified Veterinary Dentist, to provide training for General Practice veterinarians that want to provide a high level of dentistry for their patients. They are well-qualified veterinarians in General Practice to provide safe and proper oral care to your loved ones. However, they are not board-certified specialists.

What are the Financing Options?

We understand that dental surgery is expensive, especially in later stages of disease.

Financing is available through ScratchPay or Humm.

You can apply online by clicking the link on our Client Resources tab.



TOOTH RESORPTION

Presqu'ile Animal Hospital

46 Price Edward St. Unit 11
Brighton, ON Canada

Call or text: 613-475-5510
info@presquileanimalhospital.com

For more details, visit our website
www.presquileanimalhospital.com



What is Tooth Resorption?

Tooth resorption occurs when a tooth is being attacked by the immune system. This results in disintegration of the tooth, typically at the gumline and spreading down the root(s) of the tooth.

Cats are especially predisposed and in some cases, resorption is widespread throughout many of the teeth. 26-67% of cats are diagnosed with tooth resorption.

This is a painful and progressive disease process and while the pain may not be enough to stop a pet from eating, it is severe enough to warrant immediate treatment.

Diagnosis

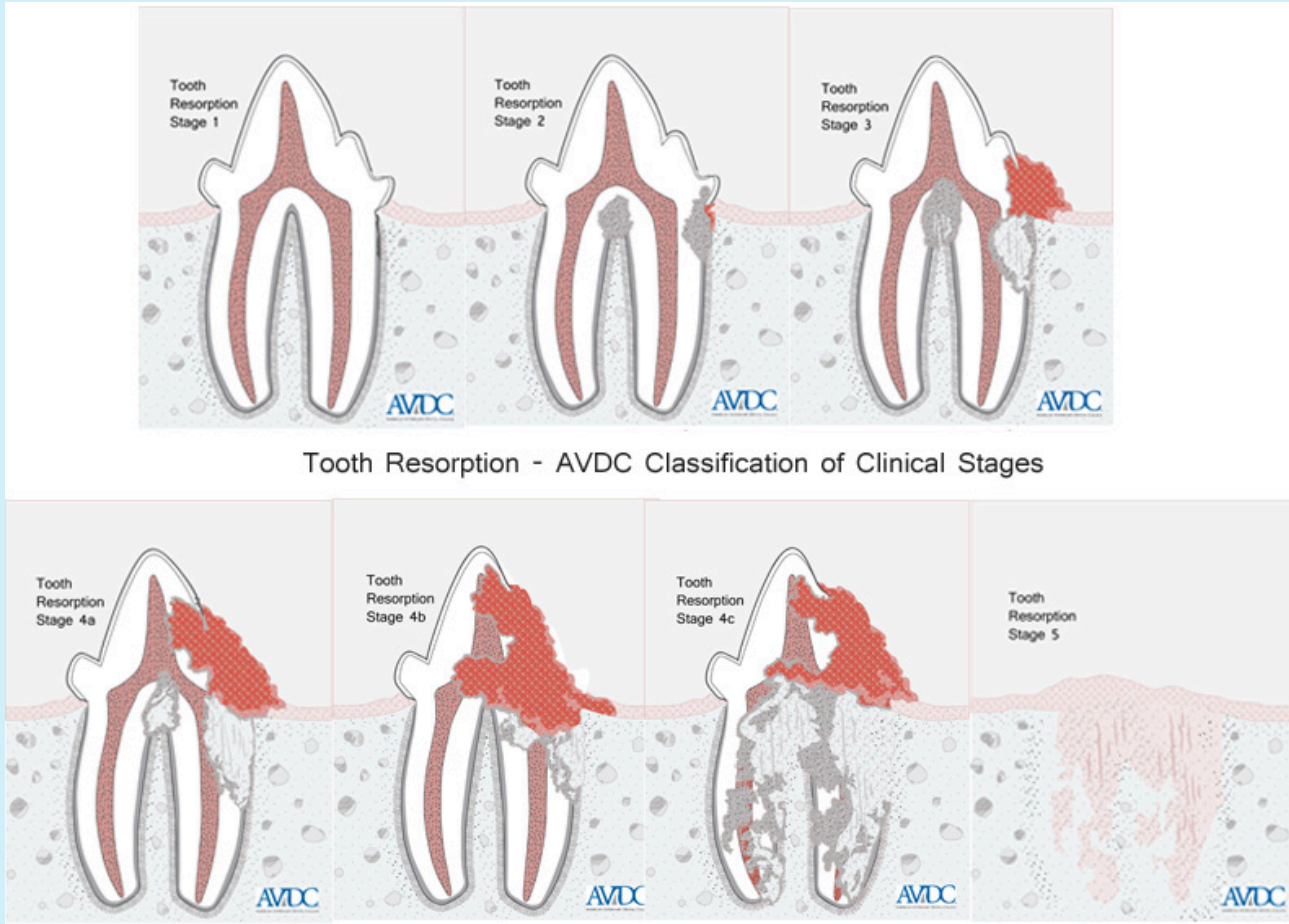
During an awake oral examination, we may see resorptive lesions that are occurring at the gumline, as shown in the pictures to the right.

Treatment

When a patient is diagnosed with tooth resorption, **the affected teeth must be extracted** to control the pain associated with the disease. In some types of tooth resorption, the crown of the tooth is amputated and the resorbing root is left in place.

Intraoral dental radiographs allow us to determine the treatment plan for each affected tooth based on the type of tooth resorption present

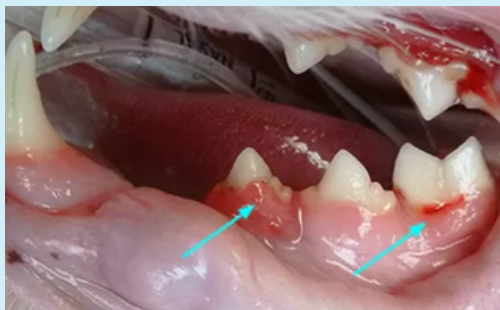Stages of Tooth Resorption



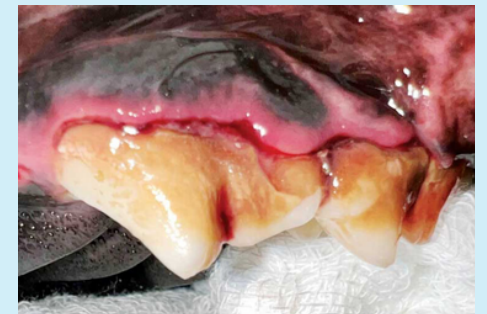Tooth Resorption - AVDC Classification of Clinical Stages

What Does it Look Like?

There are both stages and grades of resorption, which are shown in this brochure. To the naked eye, resorption often looks like gingivitis growing over the tooth.



Feline Tooth Resorption
- Veterinary Dental Center Image



Canine Tooth Resorption
- Veterinary Practice News Image